



[OSU HOME](#) | [EXTENSION HOME](#) | [ONLINE CATALOG](#) | [ORDERING INFORMATION](#)

## Extension Service

A Pacific Northwest Extension Publication  
Oregon State University, Washington State University, University of Idaho

### White muscle and other selenium-responsive diseases of livestock

PNW 157-E  
Revised May 1993  
D. Hansen, R. Hathaway, J.E. Oldfield

---

#### Do you want to print a copy?

We recommend downloading the [print version](#) (343 K).  
First download the free [Adobe Reader](#), if you don't already have it.

---

#### Contents

[Effects of selenium deficiency](#)  
[Defining the selenium status of animals](#)  
[How animals are supplied with selenium](#)

---

Oregon State University researchers made a significant discovery in 1958. They found that the underlying cause of white muscle disease is a dietary deficiency of the trace element selenium (Se). There is a fairly clear-cut relationship between soil, plant, and animal factors.

Certain soils, including some formed by volcanic action in the Northwest within the past 10,000 years or so contain practically no selenium. As a result, plants grown in them are seriously selenium-deficient. This deficiency is passed on to animals eating these plants as fresh forage, hay, or silage as all or most of their diet.

In addition to the amount of selenium in these volcanic soils, the supply is affected by intensive cropping practices. Irrigation tends to leach selenium out of the topsoil, and the application of some commercial fertilizers that result in higher crop yields reduces the percentage of selenium in the forage.

[top](#)

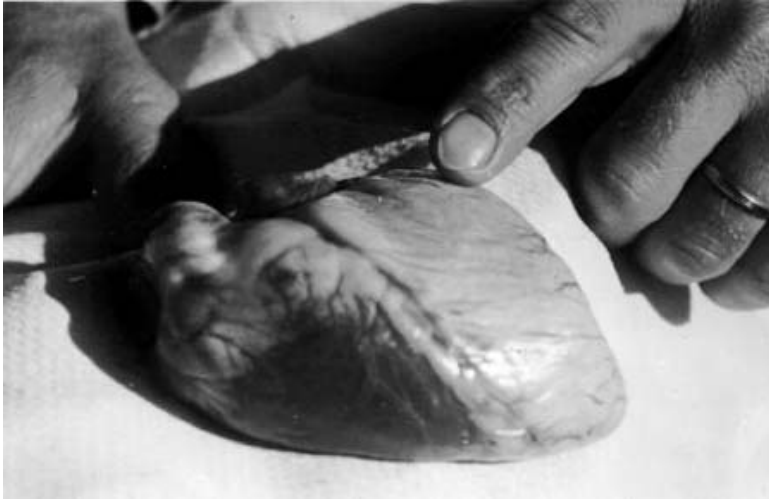

Figure 1.--Calf heart severely damaged by "white muscle disease." Note the light color of the affected ventricle. This animal died spontaneously from heart failure.

[top](#)

### **Effects of selenium deficiency**

Selenium deficiency in Northwest domestic animals has been aptly named "white muscle disease," and damages muscle tissue (myopathy). In the course of this damage, calcium salts may be deposited among the muscle fibers in certain parts of the bodies of affected animals. These salts give the areas involved a whitish appearance (See figure 1).

Both skeletal muscles, such as those of the legs and back, and heart muscles may be affected. When skeletal muscles are affected, young animals may have difficulty walking and may be unable to rise and nurse (See [figure 2](#)). When the heart is affected, the animal may die from sudden heart failure.

Some animals show signs of respiratory distress and may be treated by the owner for pneumonia. They do not respond to antibiotic therapy, and death may occur as a result of fluid accumulation in the lungs. White muscle disease is most common in newborn lambs or calves, which will show clinical signs from birth to an age of 4 to 6 weeks. It occurs occasionally in yearlings or older animals.

Cows or ewes receiving a selenium-deficient diet during gestation may give birth to offspring suffering from this trace-mineral deficiency. Their calves or lambs may be born dead or weak and die during the first few days of life. In cases of extreme deficiency, permanent damage may occur, and, the newborn animals will not respond to selenium administration. In these instances, it is necessary to provide the dams with adequate selenium during gestation. This is accomplished by injecting the pregnant cows or ewes with commercially available injectable selenium salts which are combined with Vitamin E or by providing an adequate selenium source in the diet.

The influence of selenium supplementation on the livability of newborn calves has been observed in a number of beef herds. Some calves in selenium-deficient herds have impaired structure and function of the thyroid gland. Further, selenium deficiency suppresses the immune system response, interfering with its ability to fight infection and lowering resistance to disease. These problems for the newborn can mean the difference in their survival or death.

A less acute deficiency of this trace element also contributes to chronic health problems of yearling and adult animals. Many of these animals develop a long lasting disease and are unable to utilize feed properly, and may die. Their hair coat may develop a blanched or washed-out appearance. Many affected animals have a rough hair coat and do not shed normally in the spring to develop a normal, healthy, sleek appearance.

An increased incidence of retained fetal membranes has been documented in cows on selenium-deficient diets. The problem has been alleviated by adequate selenium supplementation. Retention of fetal membranes beyond 24 hours contributes to infection of the uterus and may impair subsequent breeding ability.

[top](#)



Figure 2.--Calf showing difficulty using forelegs, a characteristic of white muscle disease. This problem can be prevented or corrected by careful administration of selenium.

[top](#)

### Defining the selenium status of animals

Occurrence of white muscle disease in one or more young animals is definite evidence of selenium deficiency in the herd. But this is a costly method of detection in that it may entail some deaths and such production losses as impaired growth of the young or lowered reproduction efficiency.

The content of selenium in blood is a reliable indicator of the selenium status of animals. Blood samples should be collected in heparinized vacutainer tubes and submitted to a reliable analytical laboratory for selenium determination.

We consider 0.04 ppm selenium to be the minimum acceptable blood level for beef cows. Breeding ewes and dairy cows require more of this mineral, and their respective blood levels should be over 0.05 and 0.07 ppm. See figure 3 for details.




Figure 3.-Relationship of selenium levels in the blood to animal health. Measurements are in parts per million.

[top](#)

### How animals are supplied with selenium

The oldest accepted method of providing needed selenium is by injection. Several preparations that contain both selenium and vitamin E are available commercially. The manufacturers of these products have carefully calculated safe and effective dosage levels for livestock species. Follow the manufacturer's recommendations and cautions closely.

Some manufacturers do not recommend injections for pregnant ewes because adverse reactions including death have been reported.

Several other methods of selenium supplementation have been developed. selenium may be given combined with feed or in salt mixes offered to animals free choice.

The Food and Drug Administration currently allows 0.3 ppm of selenium in complete feeds, with corresponding levels in salt mixes calculated on the proportion of salt to the total feed intake.

Selenium is usually obtained as one of its salts, usually sodium selenite,  $\text{Na}_2\text{SeO}_3$ . Because the amounts of selenium needed are so small, mixing can cause problems. We recommend using commercial supplementmixing facilities.

Selenium has also been given effectively in the form of commercial boluses, which lodge in the fore-stomach of ruminant animals and gradually release selenium to the animal over a 120-day period. In New Zealand and Finland, selenium has been mixed with such fertilizers as superphosphate and spread on pastures where forage is known to be selenium-deficient. Ten grams of selenium per hectare, usually supplied as sodium selenite or selenate, are sufficient to prevent selenium deficiency in grazing livestock.

Plants do not require selenium for normal growth, but they provide a useful means of preventing selenium deficiency. Like some other nutrients, selenium is dangerous to animals if given in excess. The problem is especially critical with selenium because the animal's requirement for it is extremely low (in the area of 0.1 ppm of the diet dry matter; that is, 1/10 part of selenium per million parts of dry feed). Excessive amounts of selenium cause toxicity problems in animals, including death.

Recent publicity has described problems of selenium toxicity resulting from concentrations of selenium in irrigation runoff water in the San Joaquin Valley of California. This is a reminder that excess selenium is dangerous, and that one must be careful when administering selenium to overcome deficiencies. There is no evidence that treatment of animals with selenium at the levels suggested in this publication contributes to an excess of selenium in the environment.

The map in Figure 4 shows selenium content of forages generally available to livestock in certain areas. United States Department of Agriculture soil scientists developed this map in 1968 based on an analysis of forage samples collected in the Pacific Northwest. The selenium-deficient areas conform closely to the incidence of white muscle disease in animals as reported by veterinarians.

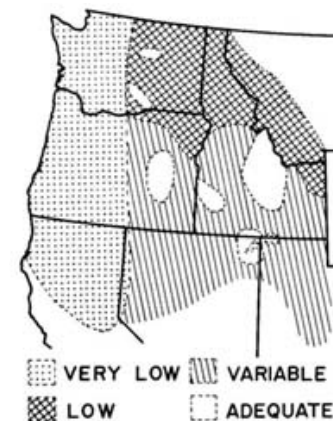


Figure 4.--General level of selenium in Pacific Northwest ranges.

[top](#)

---

Prepared by Donald Hansen, Extension veterinarian; Ronald Hathaway, Extension agent, Klamath County; and J.E. Oldfield, professor emeritus of animal science, Oregon State University.  
Revised May 1993.

---

Published and distributed in furtherance of the Acts of Congress of May 8 and June 30, 1914, by the Oregon State University Extension Service, Washington State University Extension, University of Idaho Cooperative Extension System, and the U.S. Department of Agriculture cooperating.

The three participating Extension Services offer educational programs, activities, and materials--without regard to race, color, religion, sex, sexual orientation, national origin, age, marital status, disability, and disabled veteran or Vietnam-era veteran status--as required by Title VI of the Civil Rights Act of 1964, Title IX of the Education Amendments of 1972, and Section 504 of the Rehabilitation Act of 1973. The Oregon State University Extension Service, Washington State University Extension, and University of Idaho Extension are Equal Opportunity Employers.

[Copyright](#) © 1995- 2011 Oregon State University. [Disclaimer](#).